

Erythema chronicum migrans – a tickborne spirochetosis

Willy Burgdorfer, Alan G. Barbour, Stanley F. Hayes, Olivier Péter, and André Aeschlimann

Summary

After detection of a spirochete in *Ixodes dammini*, the incriminated vector of Lyme disease in the United States, a survey was initiated to determine the presence of spirochetes also in *I. ricinus*, the suspected tick vector of erythema chronicum migrans (ECM) in Europe.

Of 201 starved female *I. ricinus* from Seewald in the western part of Switzerland, 73 (36.3%) harbored spirochetes morphologically indistinguishable from the *I. dammini* spirochete. In 69 of these infected ticks, spirochetal distribution was limited to the diverticula of midgut; a generalized infection including hemolymph was detected in only 4 ticks. Of an additional 180 female ticks that had fed on New Zealand white rabbits before dissection and microscopic examination, 39 (21.7%) were infected; 37 of these had an infection limited to the midgut, 2 a generalized infection of all the tissues. Rabbits fed on by infected ticks developed high titers of antibodies and ECM-like lesions on back and trunk as early as 4 weeks after tick feeding.

Isolation of the *I. ricinus* spirochete was readily accomplished in BSK medium.

Sera of rabbits fed on by infected *I. ricinus* or of patients who had ECM, reacted not only against the *I. ricinus* spirochete but also against the *I. dammini* organism. Similar cross reactions were recorded against the *I. ricinus* spirochetes with sera of rabbits immunized against the *I. dammini* agent and with sera of patients with Lyme disease.

Antigenic similarities of the two isolates were also established immunochemically by western blot analysis of sera from ECM and Lyme disease patients. The results suggest that the spirochete originally isolated from *I. dammini* in the United States also occurs in Europe where it is transmitted by *I. ricinus*.

In 1908, the Swedish physician, Arvid Afzelius, observed for the first time a characteristic migrating lesion on the skin of a patient bitten by

an ixodid tick. Subsequently, other cases came to his and his colleagues' attention – all with a similar clinical picture: the formation of a small annular papule that expanded centrifugally with indurated ½ to 2 cm wide borders and central clearing. In some instances the erythematous ring remained annular and gradually disappeared; in others it became irregular and remained visible for as long as 16 months. Because of the unique appearance, the syndrome was called "Erythema chronicum migrans" (Lipschütz, 1914).

The causative agent was unknown although it was speculated that it might be a virus or a toxic substance transmitted by ticks or other blood-sucking arthropods.

Hundreds of erythema chronicum migrans (ECM) cases, some with neurologic involvement (tickborne meningopolyneuritis), have since come to the attention of physicians throughout Europe, especially in regions where deer are abundant. The etiologic agent continued to elude investigators, but in view of results with slide agglutination tests, French scientists postulated that tickborne rickettsiae may be the cause of this unique syndrome (Degos et al., 1962).

Successful transmission of the disease from man to man by implantation of affected skin (Binder et al., 1955) and effective treatment with penicillin suggested that an infectious bacterial agent associated with bloodsucking arthropods, particularly the ixodid tick, *Ixodes ricinus*, was involved.

In the United States, a disease indistinguishable from ECM was first observed in Wisconsin in 1970 (Scrimanti, 1970). In 1975, a cluster of 4 cases occurred in southeastern Connecticut (Mast and Burrows, 1976). The same year, in the small community of Lyme, Connecticut, a mother whose daughter was diagnosed as having rheumatoid arthritis informed medical authorities that 11 other children in the same community had similar symptoms. This led to a

series of clinical and epidemiological investigations and to the description of Lyme arthritis or Lyme disease: an epidemic inflammatory disorder that usually begins with a skin lesion called erythema chronicum migrans (ECM) and weeks to months later may be followed by neurologic or cardiac abnormalities, migrating polyarthritis, intermittent attacks of oligoarticular arthritis or chronic arthritis in the knees (Steere et al., 1977; Steere et al., 1979; Hardin et al., 1979; Reik et al., 1979; Steere et al., 1980a; Steere et al., 1980b).

From 1975 through 1979, about 500 cases of Lyme disease were diagnosed in northeastern, midwestern, and western regions of the United States (Steere and Malawista, 1979). As in Europe, the causative agent remained unknown. Epidemiological evidence, however, suggested involvement of an infectious agent transmitted by ticks of the genus *Ixodes*, namely *I. dammini* in the northeast and midwest and *I. pacificus* in the west.

During a survey of spotted fever group rickettsiae in ticks from Shelter Island, New York – an area known for the occurrence of Rocky Mountain spotted fever and of Lyme disease – we recently detected in 77 (61.1%) of 126 adult *I. dammini*, collected off vegetation, a spirochete whose distribution within the tick appeared limited to the midgut. The organism stained moderately well with Giemsa stain and under darkfield showed a slow or sluggish movement. Isolation and culturing of the organism were accomplished by inoculating suspensions of triturated midgut diverticula of infected ticks into fortified Kelly's medium (Stoener et al. 1982). Fine structural analysis by electron microscopy revealed the spirochete to be irregularly coiled, ranging from 10 to 30 μm in length and from 0.18 to 0.25 μm in diameter. Its ends appeared tapered with 4 to 8 filaments inserted subterminally at each end. Insertion points of these filaments were in a row paralleling the cell's long axis.

The antigenic relation of the *I. dammini* spirochete to the hitherto unknown etiologic agent of Lyme disease was suggested by the reactions of patients with clinically diagnosed Lyme disease in the indirect immunofluorescence test. Persons who had been ill for up to 32 months previously had high antibody titers against the spirochete.

New Zealand white rabbits proved susceptible to the *I. dammini* spirochete. When fed on by

infected ticks or inoculated with infected tick suspensions or cultured spirochetes, they responded with high titers of antibodies. In some rabbits, skin lesions resembling ECM appeared 10 to 12 weeks later.

Since publication of these findings (Burgdorfer et al., 1982), our clinical collaborators have recovered spirochetes indistinguishable from the *I. dammini* organism from the blood of at least two patients suffering from Lyme disease (Dr. A. C. Steere – personal communication; Dr. J. L. Benach – personal communication).

Because of the clinical and epidemiological similarities between Lyme disease and ECM of Europe, we recently initiated a collaborative study with the Zoological Institute of the University of Neuchâtel, Switzerland, to determine whether *I. ricinus*, the incriminated vector of ECM in Europe, is a carrier of spirochetes. The ticks originated from the Seewald forest on the Swiss Plateau where, according to medical authorities, ECM cases had occurred sporadically in the past. The initial findings of our investigation is the subject of this paper.

Materials and methods

Description of the study area

The Seewald forest, like others of the Swiss Plateau, is a remnant of a former natural forest. Located along the east shore of the Lake of Neuchâtel in the canton of Bern, it consists of oaks, ash trees, birches, and many black alders. Conifers have been planted in many sectors. Underbrush and low vegetation are dense, especially in clearings, ravines, and hollows where irrigation provides a rich and humid soil for many grasses and bushes. Wild animals including deer, wild boars, foxes, hares, rodents, insectivora, and birds are abundant. The area provides the climatic and biologic conditions necessary for massive populations of *I. ricinus*.

Collection and examination of ticks

Adult *I. ricinus* were collected in May 1982 by flagging vegetation with a white flannel cloth. They were placed in vials containing moistened plaster of Paris and shipped to the Rocky Mountain Laboratories. Upon arrival, the ticks were examined individually for spirochetes by

testing their hemolymph under darkfield microscopy. They were then dissected, and smears from a small portion of midgut were treated with a fluorescein isothiocyanate-labeled conjugate prepared (according to Peacock et al., 1971) from the serum of New Zealand white rabbits that had been immunized against the *I. dammini* spirochete (Burgdorfer et al., 1982). An additional 400 ticks, in pools containing 25 ♀♀ and 25 ♂♂, were fed on each of 8 New Zealand white rabbits. Ticks were confined in metal capsules held in place by adhesive tape. When the engorged females detached, they were placed individually into glass vials and stored at 100% relative humidity until oviposition was completed. All spent females were examined for spirochetes as outlined above. Male ticks were not examined; they do not feed as adults.

Isolation of spirochetes from infected *I. ricinus*

The remaining midgut tissues of 8 infected *I. ricinus* females were triturated in 1.0 ml of BSK medium (Barbour et al., 1982b). The resulting suspension was diluted 30, 300, 3,000 and 30,000 fold in tubes containing BSK medium. The tightly sealed tubes were then incubated at 35°C and periodically examined for spirochetes.

Transmission and scanning electron microscopy

For ultrastructural analysis, diverticula of infected ticks were removed and processed according to methods of Hayes and Burgdorfer (1979). For negative staining, cultured spirochetes washed twice with phosphate-buffered saline (PBS), pH 7.4 were applied to parlodion-coated copper grids and stained with 2% ammonium molybdate (pH 6.6). Grids with thin sections or negatively stained spirochetes were examined with a Hitachi HU-11E-1 electron microscope. Photographs were taken on Kodak SO-163 film.

For scanning electron microscopy, aliquots of 1.5 ml BSK medium containing *I. ricinus* spirochetes were centrifuged in a microfuge (Backman Model B), for 10 minutes to pellet the organisms. The pellet was resuspended in PBS with 5 mM MgCl₂ (PBS/Mg), pH 7.4, and again centrifuged for 10 minutes. This was repeated and the pelleted material was then suspended in

PBS combined with the fixative (Hayes and Burgdorfer, 1979) v/v for 30 to 40 minutes at room temperature. After fixation, the material was again centrifuged and resuspended in PBS/Mg, pH 7.4 and applied to 12 mm circular glass coverslips that had been pretreated with polylysine HCl at 1 mg/ml of distilled water. After 30 minute adsorption of spirochetes, the coverslips were passed through a graded acetone series for 10 minutes per each concentration without allowing the samples to dry. The coverslips, specimen side up and separated from each other by copper O-rings, were then loaded into a metal basket. The acetone was removed by putting the coverslips through 5 changes of liquid CO₂. After drying in a Balzer Union critical point apparatus, they were returned to atmospheric pressure. Mounted on aluminium studs with super glue, they were spotted with silver along the margin of the coverslip and coated with 200–300 Å of gold in a SPI (Structure Probe Inc.) sputter coater.

To illustrate spirochetes in midgut tissues of infected ticks, diverticula were opened and flattened under a small amount of BSK medium. The specimens were then fixed according to Hayes and Burgdorfer (1979) and processed as outlined above.

Examination was done in an ETEC Autoscan scanning electron microscope at 20 kV. Micrographs were recorded on type 55 positive/negative Polaroid film.

Serologic testing of rabbit and human sera

The immune responses of rabbits fed on by infected *I. ricinus* and of persons with diagnosed ECM were determined by indirect immunofluorescence as outlined previously (Burgdorfer et al., 1982). *I. ricinus* spirochetes cultured in BSK medium were used as antigen. The sera were also evaluated for antibodies against the *I. dammini* spirochete (New York isolate). Similarly, sera of rabbits immunized against the *I. dammini* spirochete and sera of patients with Lyme disease were tested for antibodies to the *I. ricinus* isolate.

Immunochemical analysis of antibody-antigen reactions

The immune responses of patients with ECM and Lyme disease were also subjected to the

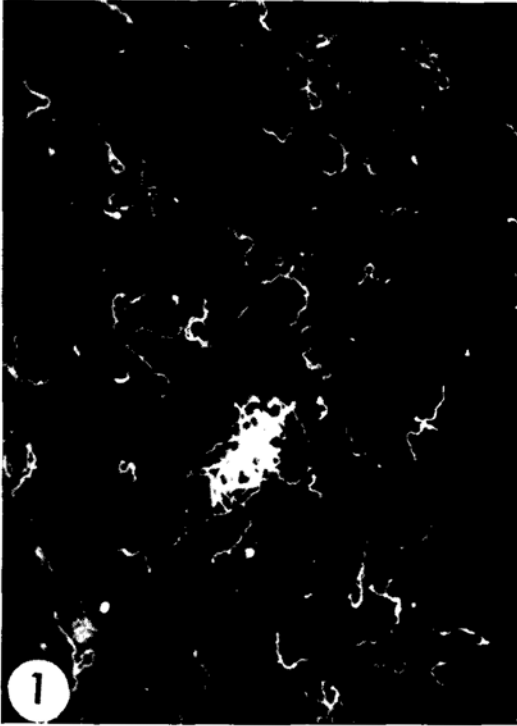


Fig. 1. Spirochetes in midgut smear of *I. ricinus*. Direct fluorescent antibody staining with a conjugate prepared from sera of rabbits immunized against the *I. dammini* spirochete (750 \times).



Fig. 2. Scanning electron micrograph of *I. ricinus* spirochetes in BSK medium (bar = 1.0 μ m).

western blot analysis (Towbin et al., 1979). This procedure involves the separation of proteins in spirocheteal lysates by sodium dodecyl-sulfate polyacrylamide gel electrophoresis (SDS-PAGE), the electrophoretic transfer of proteins to nitrocellulose, the incubation of blots with antisera, and the detection of reactions with 125 I-labeled protein A by autoradiography. For details see Barbour et al. (1982a).

Results

Detection of spirochetes in *I. ricinus*

Of 201 individually examined unfed adult ticks, 73 (36.3%) were infected with spirochetes. The organisms were limited to the midgut in 69 ticks but were found in all the tissues including hemolymph in 4 ticks. As illustrated in Figure 1, the spirochetes reacted strongly with FITC-la-

beled antibodies to the *I. dammini* isolate. Of the additional 180 females that had fed on rabbits and survived feeding and oviposition, 39 (21.9%) were infected. Two showed a generalized infection whereas the remaining 37 contained spirochetes only in their midgut. Both females with generalized infection oviposited properly and each revealed intensive spirocheteal infections of ovarial tissues. Examination of larval progeny resulted in filial infection rates of 100 and 60%, respectively.

Isolation of spirochetes from *I. ricinus*

Isolation of the spirochete in BSK medium was readily accomplished. Tubes inoculated with the 3,000-fold dilution of the infected tick suspension were positive as early as 7 days after inoculation. At 35 $^{\circ}$ C the organism grew well with a generation time of about 12 hours (Figure 2).



Fig. 3. *I. ricinus* spirochete negatively stained with 2% ammonium molybdate (bar = 2.0 μ m).



Fig. 4. Electron micrograph of the *I. ricinus* spirochete. Inset shows cross section with arrows pointing to 6 filaments (bar = 0.2 μ m; inset bar = 0.1 μ m).

Morphological characterization of the *I. ricinus* spirochete

In gross and fine structural morphology, the *I. ricinus* spirochete in its vector or in BSK medium appeared indistinguishable from the previously described *I. dammini* spirochete (Burgdorfer et al., 1982). Irregularly coiled, it ranges from 10 to 30 μ m in length and from 0.18 to 0.25 μ m in diameter. Its ends are also tapered, and from 6 to 8 filaments are inserted subterminally at each end (Figures 3 and 4). As on the *I. dammini* spirochete, insertion points of the filaments are located in a row paralleling the cell's long axis.

Susceptibility of rabbits to the *I. ricinus* spirochete

Of the 8 rabbits that served as blood donors for the 200 *I. ricinus* females, 7 were fed on by as

few as one to as many as 19 infected ticks. When tested for antibodies by indirect immunofluorescence 28 days after the engorged ticks had dropped, all 7 rabbits had titers ranging from 1:40 to > 1:1,280. The rabbit fed on by negative ticks did not have antibodies.

As early as 4 weeks after tick feeding, multiple lesions appeared on the back and lateral trunk of each seropositive rabbit. Small annular papules at first, they gradually enlarged to annular or irregularly shaped erythematous lesions, 3 to 5 cm in diameter, that were surrounded by a narrow, dark-red border (Figure 5). By the 12th week after tick feeding these lesions were still detectable in some rabbits, but had disappeared in others.

Relationship between the *I. ricinus* spirochete and ECM

The sera of 2 Swiss patients (M.L. and J.P.Gl.) with diagnosed ECM had antibody titers of

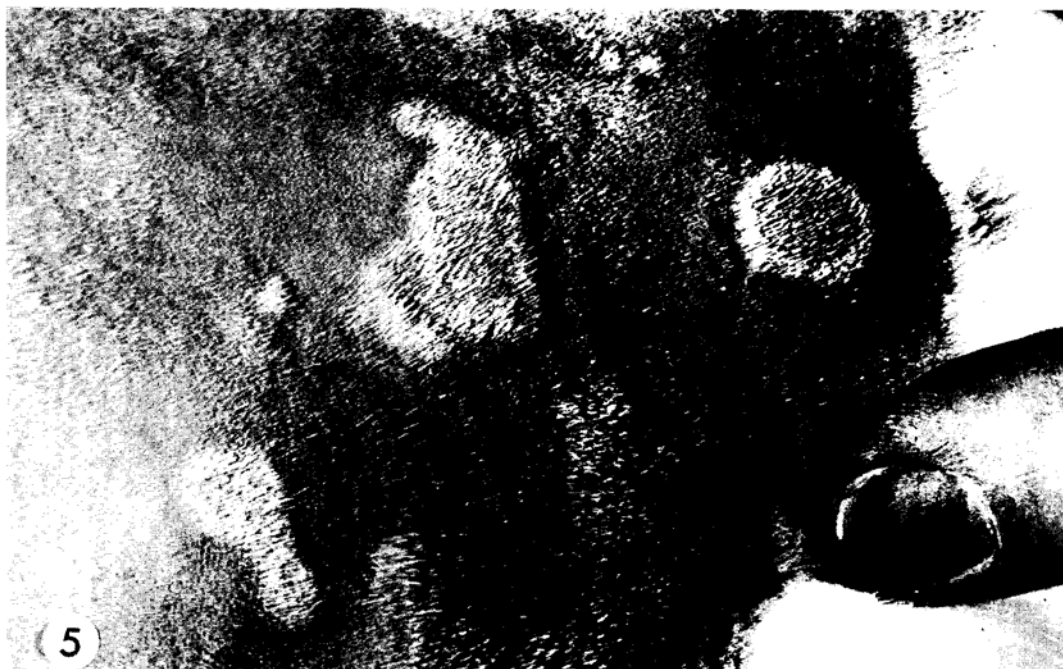

Fig. 5. ECM-like lesions on the trunk of a rabbit fed on by infected *I. ricinus* 12 weeks previously.

> 1:1,280 and 1:80 respectively against the *I. ricinus* spirochete whereas sera of 2 persons who had never experienced this illness were nonreactive.

Identity of the *I. ricinus* spirochete as the etiologic agent of ECM was also demonstrated by the results of the western blot analysis of the serum from patient M.L. As seen in Figure 6, positive reactions were obtained against several protein bands of the *I. ricinus* spirochete.

Antigenic similarities between *I. ricinus* and *I. dammini* spirochetes

As summarized in Table 1, sera from rabbits immunized by exposure to ticks infected with *I. ricinus* spirochetes and from patients diagnosed as having had ECM, had antibodies that reacted in a similar often identical way to both the *I. dammini* spirochete and the *I. ricinus* spirochete. The same was true for rabbits fed on by

Table 1: Cross reacting antibodies against the *I. ricinus* and *I. dammini* spirochetes in immune rabbits and patients

Immune Host:	Immunized by:	Reciprocal indirect immunofluorescence titers against	
		<i>I. ricinus</i> spirochete	<i>I. dammini</i> spirochete
Rabbit No. 3335	Feeding of infected <i>I. ricinus</i>	640	640
No. 3336	Feeding of infected <i>I. ricinus</i>	1,280	1,280
ECM patient M.L.	tick	1,280	1,280
J.P.G1.*	?	80	160
Rabbit No. 3092	Feeding of infected <i>I. dammini</i>	640	640
No. 3093	Feeding of infected <i>I. dammini</i>	640	960
Lyme disease patient J.G.**	tick	640	1,280
C.T.**	tick	320	320

* Diagnosed by Dr. J.P. Jeanneret, Neuchâtel, CH.

**Diagnosed by Dr. E. Grunwaldt, Shelter Island, New York, USA

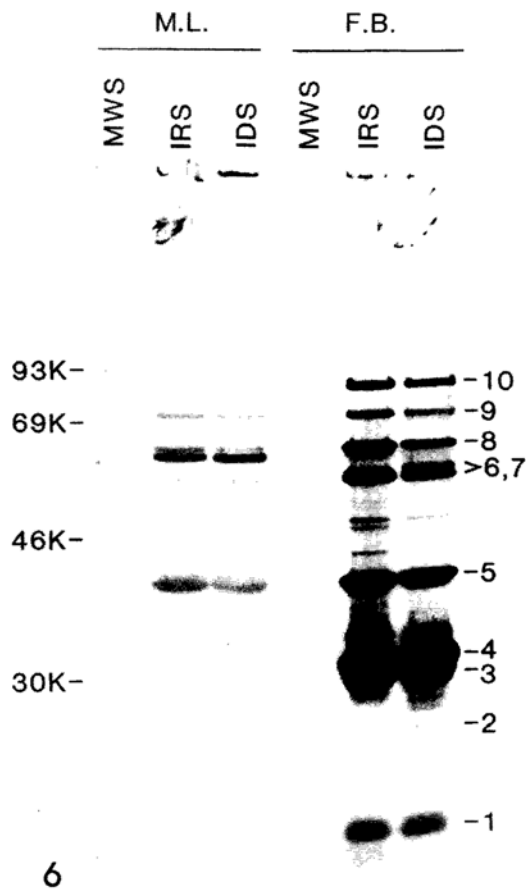


Fig. 6. Western blot analysis of antigens in the *I. ricinus* (IRS) and *I. dammini* (IDS) spirochetes. Proteins in whole cell lysates were separated by SDS-PAGE, then transferred to nitrocellulose, incubated with 1:100 dilutions of sera from ECM patient M.L. and Lyme disease patient F.B., and probed with 125 I-labeled protein A. Molecular weight standards (MWS) are indicated on the left. Intensely emitting bands in the F.B. serum are arbitrarily numbered 1 to 10. Note the close similarities of reactions of sera for both the IRS and IDS spirochetes.

Discussion

Isolation from *I. ricinus* from Switzerland of a spirochete morphologically and immunologically indistinguishable from the spirochete recently recovered (Burgdorfer et al., 1982) from *I. dammini* on Shelter Island, New York, not only suggests that the *I. ricinus* spirochete is the etiologic agent of ECM in Europe but also supports the hypothesis that ECM of Europe and Lyme disease of the United States are different expressions of the same infectious process.

Absence of arthritis and arthralgias in ECM of Europe has led to the consensus that Lyme disease in the United States is a clinically distinct disease entity far more complex and severe than ECM. Nevertheless, recent clinical reviews (Reik et al., 1979) of neurologic manifestations in Lyme disease and ECM stress their striking similarities and suggest that joint involvement may have been overlooked early in the course of ECM or may have been attributed to other causes later on. The presence of ECM cases indistinguishable from Lyme disease has recently been reported from Switzerland (Gerster et al., 1981) and France (Charmot et al., 1982, Mallecourt et al., 1982).

In an analysis of the natural histories of ECM and Lyme disease, one has to recognize the deer – the roe deer (*Capreolus capreolus*) in Europe, and the white-tailed deer (*Odocoileus virginianus*) in the United States – as a common factor. Indeed, the deer is a preferred host of all those ixodid ticks that thus far have been incriminated as vectors of ECM spirochetes, i.e., *I. ricinus*, *I. dammini*, and *I. pacificus*, and therefore should be the prime target in the search for a spirochete reservoir in nature. In support of this are the most recent findings by our collaborators of the New York State Health Department (Dr. E. M. Bosler – personal communication) who isolated a spirochete from a fawn,

infected *I. dammini* and for patients with Lyme disease. With few exceptions, their antibody titers to the *I. ricinus* spirochete and to the *I. dammini* agent were of the same magnitude. Shared antigenic determinants were also demonstrated by western blot analysis of sera from ECM patient M.L. of Switzerland and Lyme disease patient F.B. of Connecticut (kindly provided by Dr. A. Steere, Yale University, New Haven, Connecticut). There were only minor differences between the *I. ricinus* spirochete and the *I. dammini* spirochete in the antigens that reacted with immunoglobulins in the two sera (Fig. 6). M.L.'s serum contained antibodies that detectably bound to fewer antigens than F.B.'s antibodies in this analysis. Sera from 2 Swiss controls and 2 Connecticut controls did not contain antibodies that detectably bound any spirochete component in blots (data not shown).

and detected spirochetes in blood smears from 8 of 11 deer killed on Shelter Island, New York. The ixodid tick, *I. ricinus*, is the most widely distributed tick of Europe. In Switzerland, it is especially abundant in forested areas along the lake shores on the Swiss Plateau where it parasitizes a large variety of small, medium-sized, and large animals including deer (Aeschlimann, 1972). Like *I. dammini*, all developmental stages of *I. ricinus*, but particularly larvae and nymphs, readily feed on man. It is well-known that the tick plays a more or less important role as a vector of several animal and human pathogens including tickborne encephalitis virus, *Babesia divergens* and *B. bovis*, several rickettsiae of the spotted fever group, *Coxiella burnetii*, microfilariae, and trypanosomes (reviewed by Aeschlimann et al., 1979). Its role in the ecology and epidemiology of ECM, although long suspected, is currently being defined at the Rocky Mountain Laboratories. Little is known about the relation of the recently isolated spirochetes to their tick vectors. That the spirochete is limited to the midgut diverticula in most *I. ricinus*, raises the as yet unsolved question of how it is transmitted to a

host. Answers may soon be provided as a result of studies now in progress in our laboratories on the development of spirochetes in *I. ricinus* and *I. dammini*.

Many fascinating and challenging clinical questions also remain to be solved. For example, the pathogenesis of the ECM lesion(s) needs to be explained. As yet, it is not known whether their appearance is associated with the presence of spirochetes. In the present study, we again noted the appearance of multiple ECM-like lesions on back and trunk of New Zealand white rabbits weeks after infected *I. ricinus* fed on them. Their similarity to the cutaneous lesions described by Burgdorfer et al. (1982) in rabbits fed on by infected *I. dammini* and their nonoccurrence in rabbits fed on by normal ticks suggest that they represent an expression of the disease process.

Availability of the BSK medium for culturing spirochetes and of sophisticated immunological and immunochemical research techniques make it possible to address the above questions now. Thus, one may predict with confidence that a medical mystery recognized as early as 1908 is nearing solution.

Literature

- Aeschlimann, A. 1972: *Ixodes ricinus*, Linné, 1758 (*Ixodoidea*; *Ixodidae*). Essai préliminaire de synthèse sur la biologie de cette espèce en Suisse. *Acta Tropica*, 29, 321-340.
- Aeschlimann, A., Burgdorfer, W., Matile, H., Péter, O., Wyler, R. 1979: Aspects nouveaux du rôle de vecteur joué par *Ixodes ricinus* L. en Suisse. Note préliminaire. *Acta Tropica*, 36, 181-191.
- Afzelius, A. 1921: Erythema chronicum migrans. *Acta Dermatologica-Venereologica*, 2, 120-125.
- Barbour, A. G., Tessier, S. L., Stoenner, H. G. 1982a: Variable major proteins of *Borrelia hermsii*. *Journal of Experimental Medicine*, 156, 1312-1324.
- Barbour, A. G., Burgdorfer, W., Hayes, S. F., Péter, O., Aeschlimann, A. 1982b: Isolation of a cultivable spirochete from *Ixodes ricinus* ticks of Switzerland. *Current Microbiology*, 8, 123-126.
- Binder, E., Doepfner, R., Hornstein O. 1955: Übertragung des Erythema chronicum migrans von Mensch zu Mensch in zwei Passagen. *Klinische Wochenschrift*, 33, 727-728.
- Burgdorfer, W., Barbour, A. G., Hayes, S. F., Benach, J. L., Grunwaldt, E., Davis, J. P. 1982: Lyme disease - A tick-borne spirochetosis? *Science*, 216, 1317-1319.
- Charmot, G., Rodhain, F., Perez, C. 1982: Un cas d'arthrite de Lyme observé en France. *La Nouvelle Presse Médicale*, 11, 207-208.
- Degos, R., Touraine, R., Arouete, J. 1962: L'Erythema chronicum migrans (Discussion d'une origine rickettsienne). *Annales de Dermatologie et Syphilis*, 89, 247-260.
- Gerster, J. C., Guggi, S., Perroud, H., Bovet, R. 1981: Lyme arthritis appearing outside the United States: a case report from Switzerland. *British Medical Journal*, 283, 951-952.
- Hardin, J. A., Steere, A. C., Malawista, S. E. 1979: Immune complexes and the evolution of Lyme arthritis. *The New England Journal of Medicine*, 301, 1358-1363.
- Hayes, S. F., Burgdorfer, W. 1979: Ultrastructure of *Rickettsia rhipicephali*, a new member of the spotted fever group rickettsiae in tissues of the host vector *Rhipicephalus sanguineus*. *Journal of Bacteriology*, 137, 605-613.
- Laemmli, U. K., Favre, M. 1973: Maturation of the head of bacteriophage T₄. I. DNA packing events. *Journal of Molecular Biology*, 80, 575-599.
- Lipschütz, B. 1914: Über eine seltene Erythemaform (Erythema chronicum migrans). *Archiv für Dermatologie und Syphilis*, 118, 349-356.
- Mallecourt, J., Landureau, M., Wirth, A. M. 1982: La maladie de Lyme. Un cas clinique observé en Eure-et-Loir. *La Nouvelle Presse Médicale*, 11, 39-41.
- Mast, W. E., Burrows, W. M., Jr. 1976: Erythema chronicum migrans in the United States. *Journal of the American Medical Association*, 236, 859-860.
- Peacock, M., Burgdorfer, W., Ormsbee, R. A. 1971: Rapid fluorescent-antibody conjugation procedure. *Infection and Immunity*, 3, 355-357.

- Reik, L., Steere, A. C., Bartenhagen, N. H., Shope, R. E., Malawista, S. E. 1979: Neurologic abnormalities of Lyme disease. *Medicine*, 58, 281-294.
- Scrimenti, R. J. 1970: Erythema chronicum migrans. *Archives of Dermatology*, 102, 104-105.
- Steere, A. C., Malawista, S. E., Hardin, J. A., Ruddy, S., Askenase, P. W., Andiman, W. A. 1977: Erythema chronicum migrans and Lyme arthritis. The enlarging clinical spectrum. *Annals of Internal Medicine*, 86, 685-698.
- Steere, A. C., Gibofsky, A., Patarroyo, M. E., Winchester, R. J., Hardin, J. A., Malawista, S. E. 1979: Chronic Lyme arthritis. *Annals of Internal Medicine*, 90, 896-901.
- Steere, A. C., Malawista, S. E. 1979: Cases of Lyme disease in the United States: Locations correlated with distribution of *Ixodes dammini*. *Annals of Internal Medicine*, 91, 730-733.
- Steere, A. C., Malawista, S. E., Newman, J. H., Spieler, P. N., Bartenhagen, N. H., 1980a: Antibiotic therapy in Lyme disease. *Annals of Internal Medicine*, 93, 1-8.
- Steere, A. C., Batsford, W. P., Weinberg, M., Alexander, J., Berger, H. J., Wolfson, S., Malawista, S. E. 1980b: Lyme carditis: Cardiac abnormalities of Lyme disease. *Annals of Internal Medicine*, 93, 8-16.
- Stoenner, H. G., Larsen, C., Dodd, T. 1982: Antigenic variation of *Borrelia hermsii*. *Journal of Experimental Medicine* (in press).
- Towbin, H., Staehelin, T., Gordon, J. 1979: Electrophoretic transfer of proteins from polyacrylamide gels to nitrocellulose sheets: procedure and some applications. *Proceedings National Academy of Sciences, USA*, 76, 4350-4354.

Addresses of the authors:

- Willy Burgdorfer
Olivier Péter
Epidemiology Branch, Rocky Mountain Laboratories, National Institute of Allergy and Infectious Diseases
Hamilton
Montana 59840
USA
- Alan G. Barbour
Laboratory of Microbial Structure and Function, Rocky Mountain Laboratories, National Institute of Allergy and Infectious Diseases
Hamilton
Montana 59840
USA
- Stanley F. Hayes
Rocky Mountain Operations Branch, Rocky Mountain Laboratories, National Institute of Allergy and Infectious Diseases
Hamilton
Montana 59840
USA
- Prof. Dr. André Aeschlimann
Zoological Institute of the University of Neuchâtel
Chantemerle 22
CH-2000 Neuchâtel 7