

# Rhinopharyngeal autologous fat injection for treatment of velopharyngeal insufficiency in patients with cleft palate

Elsa Piotet · Céline Beguin · Martin Broome · Katia Iglesias · Frédéric Olivier · Igor Leuchter · Chantal Zbinden · Judith Hohlfeld · Anthony de Buys Roessingh · Valérie Schweizer · Philippe Pasche

**Abstract** Patients with cleft palate are prone to velopharyngeal insufficiency. In minor cases or when hypernasal speech does not resolve after velopharyngoplasty, an augmentation pharyngoplasty with autologous fat can be proposed. The aim of the present study is to evaluate the short-term (within 2 months) and long-term efficiency (during the 24 months following the procedure) of our procedure in the setting of velopharyngeal insufficiency related to a cleft palate. Twenty-two patients with cleft palate related velopharyngeal insufficiency were included in this retrospective study. All patients were operated following the same technique, in the same institution. The pre- and postoperative evaluations included a nasometry, a subjective evaluation using the Borel-Maisonny score, and a nasofibroscopy to assess the degree of velopharyngeal closure. Scores of Borel-Maisonny and nasometry were compared before, shortly after the procedure (within 2 months) and long term after the procedure (within 24 months). Forty-one procedures in 22 patients with a cleft palate performed in our institution between October 2004 and January 2012 were included in the study. Nine patients had a previous velopharyngoplasty with persistent rhinolalia despite intensive speech therapy. In 14 patients the procedure was repeated because of recurrent hypernasal

speech after the first injection. The average number of procedures per patient was 1.8. Postoperative nasometry and Borel-Maisonny scores were statistically significantly improved and remained stable until the end of the follow-up (median 42 months postoperative) in most patients. Complications were rare and minor. Autologous fat injection is a simple procedure for treatment of minor velopharyngeal insufficiencies in patients with cleft palate, with good long-term results and few complications.

**Keywords** Velopharyngeal insufficiency · Fat injection · Cleft palate · Pharyngoplasty · Autologous fat

## Introduction

Velopharyngeal insufficiency (VPI) is defined as the inability to close the velopharyngeal sphincter during phonation and/or feeding, resulting in hypernasal speech and nasal regurgitation. This can be the consequence of diminished muscular contraction of the velum and posterolateral pharyngeal walls, enlarged velopharyngeal gap either by congenital anomaly, by iatrogenic cause, or a combination of the two.

E. Piotet (✉) · C. Beguin · F. Olivier · V. Schweizer · P. Pasche  
Department of Otolaryngology, Head and Neck Surgery, Lausanne University Hospital (CHUV), 1011 Lausanne, Switzerland  
e-mail: [elsapiotet@gmail.com](mailto:elsapiotet@gmail.com)

M. Broome  
Division of Maxillo-facial Surgery, Department of Otolaryngology, Head and Neck Surgery, Lausanne University Hospital (CHUV), 1011 Lausanne, Switzerland

K. Iglesias  
Clinical Research Center and Institute of Social and Preventive Medicine, Lausanne University Hospital (CHUV), 1011 Lausanne, Switzerland

I. Leuchter  
Service ORL et Chirurgie cervico-faciale, Hôpitaux Universitaires de Genève (HUG), 1211 Geneva, Switzerland

C. Zbinden · J. Hohlfeld · A. de Buys Roessingh  
Department of Pediatric Surgery, Lausanne University Hospital (CHUV), 1011 Lausanne, Switzerland

Cleft palate is the most common cause of velopharyngeal insufficiency, often due to a combination of factors. Even if the surgical closure of the velum is performed within the first months of life of these patients, some degree of fibrosis will often remain which can interfere with an optimal velar mobility. Moreover, the velum is often short in these patients, and this leads to a larger velopharyngeal gap to close during phonation and feeding. Even submucosal clefts can lead to velopharyngeal incompetence, because of the diminished contractibility of the velum caused by the absence of fusion of the musculature in the midline.

Cleft lip and palate patients are usually followed since birth by a multidisciplinary team, which includes surgeons, audiologists, phoniatrists, speech therapists and orthodontists, to resolve the numerous problems related to this condition. Concerning velopharyngeal insufficiency, speech therapy is the mainstay treatment to improve pharyngeal contractions. Reinforcement of the lateral and posterior (named Passavant's pad) pharyngeal walls by speech therapy can be sufficient to compensate mild cases of velopharyngeal insufficiency and resolve hypernasal speech. In cases of severe velopharyngeal incompetence, thus when the gap is too large and velopharyngeal closure is inferior to 50 %, a pharyngoplasty is indicated, as when the contraction of the velum is absent. In intermediate cases, when closure of the velopharyngeal space is at least 50 % and velar contraction is present, we propose our patients an autologous fat injection in the pharyngeal wall to improve velopharyngeal closure. As well, when patients have had a pharyngoplasty with persistent hypernasal speech after this procedure, we propose them a complementary autologous fat injection.

Posterior pharyngeal augmentation to improve velopharyngeal closure has been first described with Vaseline in 1900 by Gersuny [1], and followed with different types of materials used for implantation such as Teflon [2–4], silicone [5], paraffin [6], autologous cartilage [7, 8], collagen [9] and hydroxyapatite [10]. Disadvantages with synthetic materials include giant cell reaction, potential hypersensitivity and risk of migration. Despite its well-known tendency to resorption, autologous fat transfer has become a popular alternative to the synthetic material in various indications, because of its innocuity, accessibility, price and disponibility. In 1926, von Gaza [11] described a posterior pharyngeal wall autologous fat implantation by cervicotomy. Transoral autologous fat injection in the posterior wall was first described by Dejonckere [12] in 17 patients with short velum with improvement in nasometry and a mean follow-up of 9 months. Leuchter [13] showed improvement in nasometry and perceptive BM score in 18 patients with cleft palate, short velum or myopathy and a mean follow-up of 10.5 months. Recently, Lau [14]

showed good results in 11 cleft palate patients with a mean follow-up of 17 months. Because of the limited number of patients included in these studies or high variability in the etiology of their velopharyngeal insufficiency, it is difficult to obtain statistically significant results. Moreover, there is few data available in the literature about the long-term results of pharyngeal autologous fat injection, which could possibly be disappointing because of the fat pad resorption.

The aim of this study was to assess the short- and long-term efficiency of autologous fat injection (AFI) in the pharynx to relieve hypernasal speech related to moderate and light velopharyngeal insufficiency (VPI) in patients with cleft lip and palate. The secondary endpoints were to identify patients' and injection's related factors which could potentially influence on the efficiency of the procedure, and to review its potential complications.

## Materials and methods

This is a retrospective study reviewing all the procedures of AFI for VPI performed in cleft lip and palate patients in the Otolaryngology and Head and Neck surgery Department of Centre Hospitalier Universitaire Vaudois (CHUV). Twenty-three patients were operated between October 2004 and January 2012, with a total of 41 procedures. One patient was excluded from the study because the preoperative assessment was lacking. All our patients but one had a primary closure of the palate before, usually within the first year of life. All patients with severe VPI (defined as more than 50 % velopharyngeal gap during phonation) or with bad contractibility of the velum had a prior velopharyngoplasty.

Inclusion criteria to perform AFI were: (1) hypernasal speech related to sequela of unilateral cleft lip and palate; (2) previous extensive speech therapy; (3) pharyngeal closure of at least 50 % at nasofibrosopy; (4) presence of visible velar contraction.

If improvement of hypernasal speech was considered insufficient after a single injection, a new one was proposed to the patient.

All patients were operated and followed in our institution in the pluridisciplinary cleft and palate clinics and had periodic voice evaluations after AFI. Nineteen patients had a final evaluation for the study purpose, whereas the data of 4 of them were based exclusively on the charts because the patients did not want to come.

## Evaluations

The pre and postoperative assessments included instrumental and perceptual evaluation of the hypernasality and nasofibrosopy.

**Table 1** Borel-Maisonny score: perceptive evaluation of hypernasality

Score	Definition
I	Normal phonation, no nasal air emission
I-II	Good phonation, intermittent nasal air emission, good intelligibility
II-I	Phonation with partially corrected nasal air emission
IIb	Phonation with continuous nasal emission but good intelligibility
IIIm	Phonation with continuous nasal emission and poor intelligibility
III	Phonation with continuous compensatory articulation and bad intelligibility

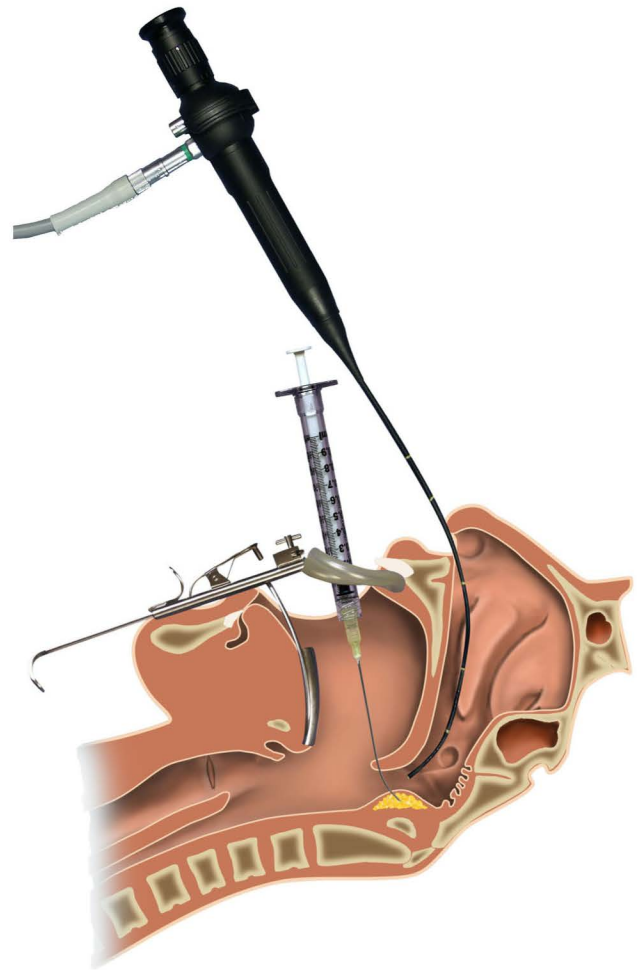
The perceptual evaluation of the voice was done by a speech therapist and an ENT doctor or phoniatician using spontaneous speech and a short phonetically equilibrated text with nasal and denasal phonemes read orally. The Borel-Maisonny score was used to rate the hypernasality. This score is based on the audible nasal emission, the intelligibility and the presence of compensatory articulation during phonation (Table 1) [15].

The quantitative assessment of nasalance was obtained using a KayPENTAX Model 6200 Nasometer. This technique consists of registering and filtering separately the acoustic energy emanating from the nose and the mouth with a microphone. The computer expresses a ratio of the nasal to nasal-plus-oral acoustic energy as a percentage, called nasalance [17]. The average nasalance value in normal French speech is defined as less than 30 % for oral phonemes. The assessment of nasalance was done using the vowels /a/, /o/, /i/, the items /pa-ta-ka/, /ba-da-ga/, four short French sentences without nasal phonemes and a short text of about 30-s reading time that contained no nasals.

The nasofibroscope was performed under local anesthesia. The degree of velopharyngeal closure was assessed during phonation of /a/, /i/, /s/, and scored as: complete, subtotal or insufficient. Presence of adenoid rests and compensatory signs (Passavant's pad, lateral pharyngeal wall contraction) were assessed. Special attention was given to identify a potential pulsating ectopic carotid artery with an aberrant course in the rhinopharynx.

### The surgery

Autologous fat injection was always performed using the same technique, under general anesthesia and as an outpatient procedure. All patients were intubated by an oral Rae tube and were given perioperative antibiotic prophylaxis. Fat was harvested in the abdomen, thigh or buttocks following the Coleman technique [18]. A skin incision of 2–3 mm was done and fat was harvested with a blunt canula under syringe aspiration. The fat was then



**Fig. 1** Transoral injection under nasofibrosopic view

centrifugated at 3,000 during 3 min resulting in separation of the blood clot and the serum which were removed. Then fat was gently introduced in several 1 ml sterilized Luer-lock syringes which are the one used for the injection with a slightly curved 20 gauze needle. Injection was done transorally with an orthostatic spatula as used for amygdallectomy (Fig. 1). A visual control during injection was done with a pediatric fiberbronchoscope. Fat was injected in the submucosa of the posterior pharyngeal wall, through the soft palate, medially and laterally if necessary, until a good closure was obtained (Fig. 2). Postoperative care included a 5 days prophylactic antibiotherapy (amoxicillin/clavulanic acid). Patients were advised to apply ice on the donor site for 24–48 h and a compressive stocking was used in cases of thigh harvest.

### Statistical analysis

To evaluate the short-term efficiency of the treatment, the scores of Borel-Maisonny and nasometry before the first

**Table 2** Description of patients

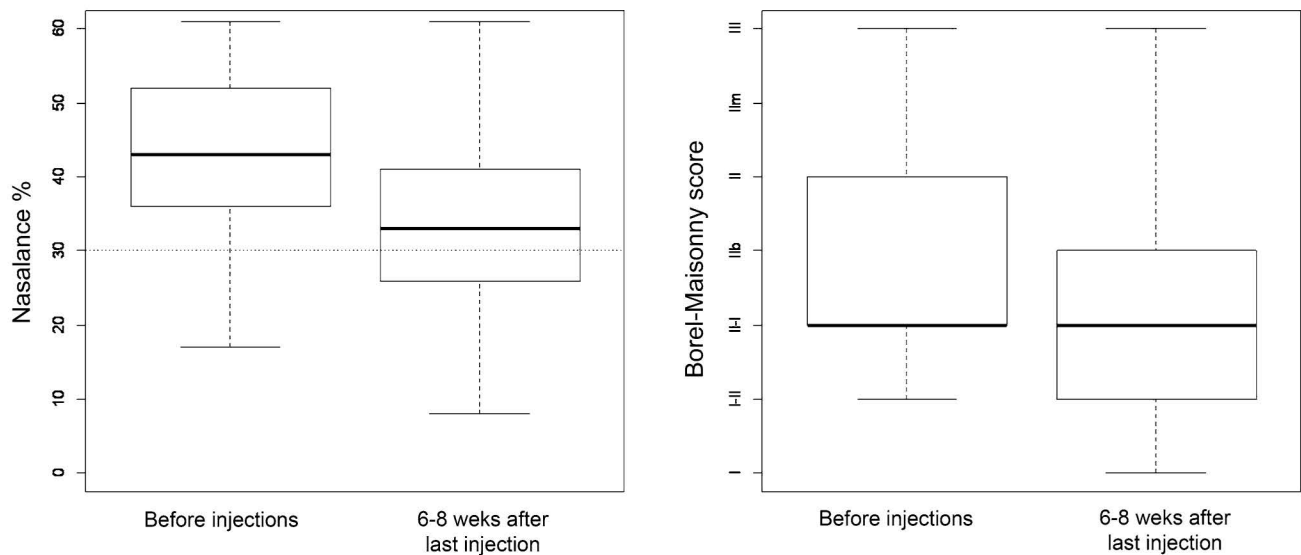
Patient	Age (years)	Pathology	Syndrome	Post Primary closure	Post pharyngoplasty	No surgery before AFI	Number of injections	Follow-up (months)
1	17	CLP		+			3	38
2	34	CLP	22q11	+	+		2	61
3	37	CP		+			2	25
4	14	CP submucosal				+	1	19
5	16	CP	PR sequ	+	+		3	25
7	11	CP		+			1	49
8	13	CP submucosal	22q11	+	+		2	25
9	12	CP		+	+		3	73
10	17	CLP		+	+		2	13
11	8	CP	22q11	+			2	17
12	11	CP		+			3	49
13	13	CP		+			2	24
14	12	CLP		+	+		2	15
15	15	CP	PR sequ	+	+		1	9
16	16	CP		+			1	76
17	10	CP		+	+		2	92
18	15	CLP		+			2	64
20	14	CP	PR sequ	+			1	13
21	43	CP		+			3	47
22	12	CLP	PR sequ	+			1	61
46	12	CP	PR sequ	+			1	42
47	17	CP		+			1	43

CLP cleft lip and palate, CP cleft palate, PR Pierre robin sequence

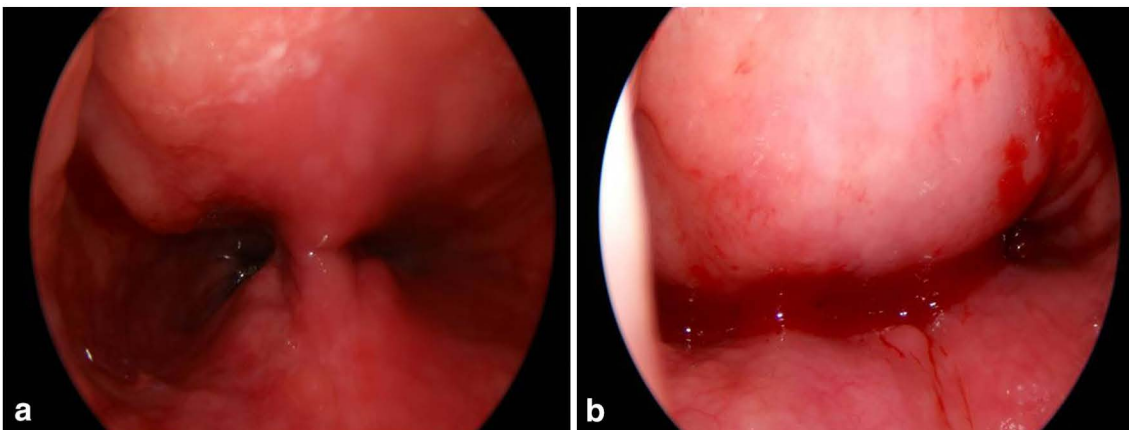
injection and between 2 and 8 weeks after the last one were compared for each patient. The limit of 2 months for the evaluation of short-term efficiency was chosen because we previously observed that a 30–50 % fat resorption occurred within this early postoperative period [13]. To evaluate the long-term efficiency, the two parameters were measured several times after the last injection up to 24 months. Multilevel models with patients as random effect were performed: first to see the effect of time (comparison of two time points for the short-term analysis and linear and quadratic time effect for the long-term analysis); second, to test patients' and injection's related factors (main effect to see the impact on overall scores and interaction with time to see if the effect of time is greater or lower in function of factors) which could potentially influence the scores. The patient's related factors were: sex, age, cleft related to a syndrome, previous pharyngoplasty, velar hypotonia and articulatory troubles. The injection's related factors were: number of procedures per patient, site of fat harvest, total volume of fat injected. Due to limited number of observations (maximum 22 at patient level and maximum 44 at measure level), we could only test time and one factor as main effect and the interaction.

## Results

Twenty-two patients, 15 female and 7 male, were included in the study. Table 2 summarizes the features of patients. The median age at time of first injection was 14 years old with 50 % of the sample aged between 12 and 17 (range 8–43). Mean follow-up after the last injection was 38 months (range 9–92 months). Twenty patients had complete cleft, among which five maxillo-labio-palatine cleft, 1 maxillo-palatine cleft and 14 cleft palate. Two patients had only submucosal cleft palate. Cleft lip and palate were part of Pierre Robin sequence in 5 patients and associated with 22q11 syndrome in 3 patients. Nine patients (41 %) had a previous velopharyngoplasty with persistent hypernasal speech after the procedure which leads to complementary autologous fat injection. Ten patients (45 %) had some compensatory articulation associated. One patient had a fatigability of the velum, namely diminution of velar contraction with prolonged phonation. The descriptive data revealed a short velum in 11 (50 %) patients and some degree of velar hypotonia in 6 (27 %) of them. Five patients suffered from some nasal regurgitation before injection, which totally disappeared in 4 of them and improved in one after the treatment.



**Fig. 2** Transnasal view in a patient with previous pharyngoplasty. **a** Before fat injection, **b** immediately after fat injection



**Fig. 3** Velopharyngeal closure, assessed by transnasal fibroscopy in 14 patients. Comparison between t0 (before any procedure) and t2 (between 12 and 24 months after the last procedure)

A total of 40 rhinopharyngeal fat injections were performed in these patients, with one to three injections in the same patient (8 patients with one injection, 10 with 2 and 4 with 3). The amount of fat injected in the posterior pharyngeal wall varied from 4 to 13 ml, with a mean of 8 ml per procedure. The most frequent donor site was the thigh ( $n = 25$ ) followed by the abdomen ( $n = 12$ ) and the buttock ( $n = 2$ ).

Nasofibroscopy showed adenoid rests in 7 patients. Degree of velopharyngeal closure assessed by fibroscopy before the procedure and at the end of follow-up is reported in Fig. 3.

#### Short-term results

Comparison of voice evaluation before any injection and between 2 and 8 weeks after the last injection was

performed in 17 patients. In 5 patients, the first postoperative voice evaluation was done more than 2 months after the last procedure and they were therefore excluded from this analysis. This showed a significant improvement in nasometry in 15/17 patients (88%), with a nasalance mean improvement of 9% ( $p < 0.001$ ). Borel-Maisonnny score was significantly improved in 10/17 patients (59%) ( $p < 0.001$ ) (Fig. 4).

Concerning the multivariate analysis of nasometry scores, the only significant influence was related to the presence of a polymalformative syndrome (Pierre-Robin sequence or 22q11 syndrome): The improvement of nasalance after injection was greater ( $p = 0.016$ ) for these patients than for those with isolated cleft. No other factors related to patients or to injections were significantly related to nasometry scores.

Concerning Borel-Maisonny score, patients with velar hypotonia or articulatory troubles had a worse mean Borel-Maisonny score ( $p = 0.014$ , respectively  $p = 0.019$ ) before and after injection.

#### Long-term results

The analysis of the quantitative and perceptual voice evaluations during 24 months after the last injection ( $n = 22$ ) did not show any time effect (nor linear: respectively,  $p = 0.796$  and  $p = 0.862$ , neither quadratic: respectively,  $p = 0.165$  and  $p = 0.183$ ).

No factors related to patients were significantly related to results of nasometry.

Concerning the multivariate analysis of perceptual voice evaluations, patients with velar hypotonia or articulatory troubles had a worse mean Borel-Maisonny score ( $p = 0.025$ , respectively  $p < 0.001$ ). On the contrary, those with adenoid rests had a better mean Borel-Maisonny score ( $p = 0.042$ ) independently of time measures.

#### Discussion

Since the first pharyngeal injection with Vaseline by Gersuny in 1900 [1], the concept of augmentation pharyngoplasty has been widely used with different materials [2–10]. Autologous fat grafting for the treatment of velopharyngeal insufficiency has been reported for about a decade in the literature. Nevertheless, the studies available in the literature concerning this procedure show great heterogeneity. Bishop reported in his recent review the lack of systematicity in the technique of fat grafting itself and in the analysis of outcome in the series published until now [16].

One major concern is the etiology of VPI: Dejonckere [11] showed good functional results (nasometry) in 17 patients with short velum with a mean follow-up of 9 months. Leuchter [13] analyzed the functional outcome of 18 patients presenting cleft palate, short velum or myopathy 10 months postoperatively. Leboulanger [19] reported 22 patients with either cleft palate or short velum and a good outcome after 17 months. Cantarella [20] does not mention the etiology of VPI in the 12 children injected in his study.

VPI in cleft palate patients is particular because there is a muscular concern in addition to the anatomical shortness of the velum. Moreover, many of these patients with severe VPI have already benefited from a velopharyngoplasty. Only 2 studies concerning AFI in cleft palate patients are available in the literature: Lau showed statistically improved nasometry and subjective hypernasality in 11 cleft patients after a mean follow-up of 17 months.

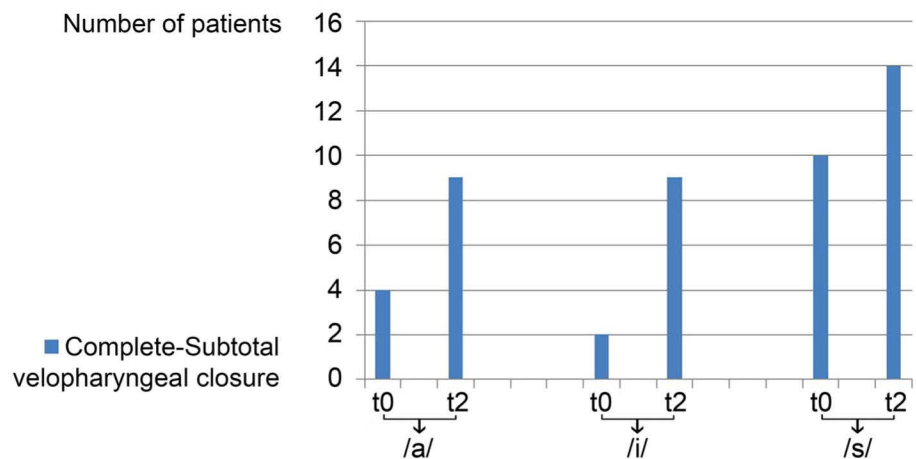
Interestingly, apnea-hypopnea index was also assessed and did not show any change after the injection [14]. In his prospective study, Cao [21] addressed 11 cleft palate patients but AFI was systematically combined with another pharyngeal surgery (velopharyngeal ring ligation, Furlow double-opposing Z plasty, buccal musculomucosal island flap, or a combination of them). Even if the results of the latter study showed a good postoperative improvement, they are difficult to interpret because of the combination of several procedures at the same time. Moreover, in this study, these patients have never had speech therapy, which is contrary to our belief that enhancing pharyngeal muscular contraction is the mainstay of the treatment of velopharyngeal insufficiency, and necessary to obtain a better functional outcome.

The major concern about fat injection, mostly used in cosmetic surgery, is resorption after transplantation. This phenomenon is well known, resulting in the necessity of overgrafting to anticipate future resorption, even if the exact tissular process after transplantation has still not been completely established in the literature: Marchand [22] histologically found a large central non-viable portion in transplanted fat 10 days after transfer. Neuhof [23] reported the death of the transplanted fat and its replacement by fibrous tissue and newly formed adipocytes. Peer [24] believed that only the core of the graft survived, but he was also the first to recommend the presence of a good blood supply near the site of transplantation. An animal study with marked transplanted fat showed a 6 months survival of 30 % when transplanted into subcutaneous tissue and 6 % into muscle [25]. Despite the poor objective results reported in the animal studies, fat injection is still a widely used method, particularly in cosmetic and reconstructive surgery, with good subjective outcome in the literature [26–28].

Many authors have tried to develop alternative technique of harvesting or processing of the graft to enhance its viability and reduce resorption, but until now there are no clearly demonstrated advantages of one technique to another [26, 27, 29, 30].

On the opposite, recent advances in the use of hematopoietic stem cells could be of real value to potentiate viability of fat transplant and reduce the need for repeated injections: Bone-marrow derived stem cells are known for their regenerative potential through transdifferentiation (stem cell plasticity), cell fusion, or cytokine-mediated effects. Local injection of these cells is investigated in many different settings to enhance cell regeneration and decrease necrosis. Recently, Jihanhui compared autologous fat graft alone and autologous fat graft with adjunction of bone-marrow derived stem cells in the setting of facial recontouring for treatment of Parry-Romberg syndrome [39]. He showed that in patients injected with stem cells 1 injection was sufficient to reach facial symmetry, while in

**Fig. 4** Short term results in nasometry and Borel-Maisonny score



the patients injected with fat alone, 1–3 injections were necessary.

In our series of 22 cleft patients, early postoperative results within 2 months after the last injection showed a statistically significant improvement in both nasometry and Borel-Maisonny score. This confirms the previously reported short-term objective and perceptive efficiency of the technique to relieve hypernasal speech. From 2 months to 2 years after the last injection, the analysis of the nasometry and Borel-Maisonny score failed to show any statistically significant change during 2 years. We therefore conclude that no significant fat resorption occurred after the first 2 months and that the injected fat remained stable. This concurs with the observational data found in the literature and our current belief that fat resorption occurs mainly during the first days or weeks after transplantation.

Nevertheless, one should point out that in this study, 64 % of patients had 2 or 3 injections to obtain the final results. This means that in most cases a single injection is not sufficient to obtain satisfactory results and that patients should be informed that 2 or 3 procedures may be necessary. This emphasizes the tendency of the fat to resorption.

These good functional long-term results in quantitative and perceptive voice evaluation are well correlated with the clinical observations made with transnasal fibroscopy. Figure 3 shows the evolution of velopharyngeal closure observed before the first procedure and at the end of the follow-up for the three phonemes.

Multivariate analysis did not show any significant correlation between the variable factors related to the injection, namely: site of fat harvesting, volume of fat injected, and number of procedures per patient did not influence on the efficiency of the procedure. We also observed that the presence of a previous pharyngoplasty did not show any influence in our statistical analysis, as well as sex and age.

The only significant factor influencing the efficiency of fat injection was the presence of a cleft-related syndrome

(Pierre Robin or 22q11) which was associated with a worse initial nasometry but greatly improved after the procedures. We do not have any clinical explanation for this better outcome in these patients.

Donor site showed no influence in efficiency and this is consistent with the data found in the literature, which fail to show any difference of fat quality between different donor sites [31, 32]. Interestingly, the volume of fat injected had no influence either. This can be explained with the fact that the transplanted fat should be located near a vascular supply. Thus, excessive amount of transplanted fat will not benefit ideal vascular supply and could be less viable, thus showing more resorption. This theory is consistent with the widely used injection technique in fat recontouring, the so-called fanning technique in which fat is injected in multiple subcutaneous tunnels [33]. This leads to deposition of small fat particles to maximize the contact with vascularized tissue and enhance survival. Technically the confec-tion of such tunnels is not possible in the posterior pharyngeal wall, and transfer of a too large amount of fat will not permit a good vascularisation in the core of the transplant. For this reason we rarely inject more than 10 ml in the posterior pharyngeal wall, and we prefer to repeat the injection 5–6 months later if a single injection is not sufficient. Thus, the fat injected during the first procedure can benefit from sufficient vascularisation which promotes its survival. After a few months, a new injection can be done in good vascularisation condition.

As expected, the mean Borel-Maisonny score before and after injection was worse for patients presenting some velar hypotonia and articulatory troubles, this last factor being directly related to the score scale. Nevertheless, presence of velar hypotonia did not show any significant difference in nasometry. This result is contrary to our current belief that mobility of the velum is an important factor to enhance compensation and close the velopharyngeal gap. This absence of statistically significant difference may be explained by the fact that patients with severe velar

hypomobility were not included in the study as we do not propose AFI in these cases. On the opposite, patients with visible adenoid rests at fibroscopy showed a better mean Borel-Maisonny score, emphasizing the natural role of the adenoid to fill the velopharyngeal gap. This confirms the important role of these structures in cleft palate patients in which they should not be removed.

Some authors advocate fat injection in the soft palate and pharyngeal arches in adjunction to posterior pharyngeal wall [20, 34, 35]. Nevertheless, our patients were all injected only in the posterior wall because we believe that the mobility of the soft palate should remain optimal. Our attitude with cleft palate patients is to improve pharyngeal contraction by intense speech therapy and propose first a velopharyngoplasty in case of large velopharyngeal gap. For intermediate cases of mild VPI or to complete the effect of a pharyngoplasty we consider autologous fat injection. Patients are informed that more than a single injection is usually required to obtain good results.

One of our patient (no 4) did not had a primary closure of the palate before AFI. This occurred because she had a submucosal cleft palate which remained undiagnosed for years and then which improved well with speech therapy. Because this child had light hypernasality with a very good velar contraction and a minor velopharyngeal gap to close, we performed only AFI without any other surgery in her, with good results after a single injection. Nevertheless this case was an exception and AFI should not be considered as an alternative to primary closure of the palate or to velopharyngoplasty in severe cases.

We did not report any major complication of autologous fat injection. All our patients complained however of some odynophagia during 3–6 days after the procedure, which is directly correlated to the injection. All patients presented also some ecchymosis and mild pain at the harvest site, which was more painful in the thigh than in the abdomen. We used to inject the pharynx in the submucosal plane, avoiding any irritation of the prevertebral fascia which could lead to the Grisel's syndrome, well known after adenoidectomy. No patients complained of neck pain after the procedure. This is consistent with literature reporting few complications after pharyngeal autologous fat injection. One case of obstructive sleep apnea has been described in a child after hypertrophy of the pharyngeal transplanted fat [36]. Devastating complications as blindness and cerebrovascular accident has been described in few cases after cosmetic facial fat injection, but have never been reported in pharyngeal wall fat injection [37]. The injection should be done strictly in the submucosal plane and great attention should be payed to the presence of a pulsating ectopic carotid vessel in the pharyngeal wall. Patients with 22q11 syndrome are known for high prevalence of vascular anomalies: Marom et al. [38] recently

reported a prevalence of 49 % medial deviation of one internal carotid artery and of 28 % submucosal internal carotid artery in these patients. The indication to perform a preoperative MRI to exclude such variation should be evaluated, especially in 22q11 syndrome patients.

In this study, we admit that the evolution of functional results, especially nasometry, is directly correlated to the stability of the transferred fat. Nevertheless, to determine the outcome of fat transfer, a pre and postoperative MRI could better show the real volume and resorption of the fat. Filip [34] showed persistence of the fat pad in the pharyngeal wall in a postoperative MRI after a median follow-up of 12 months. In our study, we admit that the persistence of the fat in the posterior pharyngeal wall, closing the velopharyngeal gap is directly proportional to the functional results. This may not reflect truly the quantity of residual fat, because transitory gap closure before resorption could help the patient to improve the compensatory mechanisms (pharyngeal contraction). Thus the stability of the functional results could also be related to an improvement of contraction, even in the presence of some long-term resorption.

Another potential bias with nasometry and Borel-Maisonny score is the variability in these measures, which could be influenced by tiredness, nasal congestion and concentration during the tests.

## Conclusion

Autologous fat injection is a sure and efficient procedure in cleft palate patients presenting mild VPI, or residual VPI after velopharyngoplasty, in adjunction to speech therapy. Functional results are stable after 2 months postoperatively with no significant change afterwards, which is related the good fat pad stability in the posterior pharyngeal wall. More than a single injection is often required to obtain satisfactory results and patients should be informed this way. Minor side effects related to pharyngeal injection and fat harvest are common, but we reported no major complications in our series. As the harvest site did not influence on the efficiency and durability of the injection, we currently preferentially harvest the fat in the abdomen which is less painful for the patient.

**Conflict of interest** None.

## References

1. Gersuny R (1980) Concerning a subcutaneous prosthesis. *Plast Reconstr Surg* 65(4):525–527
2. Bluestone CD, Mushgrave RH, Mc Williams BJ, Crozier PA (1968) Teflon injection pharyngoplasty. *Cleft Palate J* 5:19–22

3. Smith JK, Mc Cabe BF (1977) Teflon injection in the rhinopharynx to improve velopharyngeal closure. *Ann Otol Rhinol Laryngol* 86(4 Pt 1):559–563
4. Ward PH, Stoudt R Jr, Goldman R (1967) Improvement of velopharyngeal insufficiency by teflon injection. *Trans Am Acad Ophthalmol Otolaryngol* 71(6):923–933
5. Brauer RO (1973) Retropharyngeal implantation of silicone gel pillows for velopharyngeal incompetence. *Plast Reconstr Surg* 51(3):254–262
6. Hv Eckstein (1922) Hartparaffininjektionen in die hintere Rachenwand bei angeborenen und erworbenen Gaumendefekten. *Klin Wochenschr (Berl)* 1:1185
7. Trigos I, Ysunza A, Gonzalez A, Vazquez MC (1988) Surgical treatment of borderline velopharyngeal insufficiency using homologous cartilage implantation with videonasopharyngoscopic monitoring. *Cleft Palate J* 25(2):167–170
8. Desgain O, de Burbure C, Mazy C, Verheyden PJ, Monnoye JP, Levie P (2006) Autologous costochondral cartilage implant in two cases of velopharyngeal insufficiency. *B-ENT* 2:39–42
9. Remacle M, Bertrand B, Eloy P, Marbaix E (1990) The use of injectable collagen to correct velopharyngeal insufficiency. *Laryngoscope* 100(3):269–274
10. Brigger MT, Ashland JE, Hartnick CJ (2010) Injection pharyngoplasty with calcium hydroxyapatite for velopharyngeal insufficiency: patient selection and technique. *Arch Otolaryngol Head Neck Surg* 136:268–271
11. Gaza WV (1926) Ueber freie Fettgewebstransplantation in den retropharyngealen Raum bei Gaumenspalte. *Arch Klein Chir* 142:590–599
12. Dejonckere PH, van Wijngaarden HA (2001) Retropharyngeal autologous fat transplantation for congenital short palate: a nasometric assessment of functional results. *Ann Otol Rhinol Laryngol* 110(2):168–172
13. Leuchter I, Schweizer V, Hohlfeld J, Pasche P (2010) Treatment of velopharyngeal insufficiency by autologous fat injection. *Eur Arch Otorhinolaryngol* 267:977–983
14. Lau D, Oppenheimer AJ, Buchman SR, Berger M, Kasten SJ (2013) Posterior pharyngeal fat grafting for velopharyngeal insufficiency. *Cleft Palate Craniofac J* 50(1):51–58
15. Borel-Maisonny L (1975) Insuffisance vélaire, point de vue de l'orthophoniste. *Reeduc Orthoph* 13:61–81
16. Bishop A (2014) Autologous fat grafting for the treatment of velopharyngeal insufficiency: state of the art. *J Plast Reconstr Surg* 67:1–8
17. Fletcher SG (1976) Nasalance vs. listener judgements of nasality. *Cleft Palate J* 13:31–44
18. Coleman SR (1997) Facial recontouring with lipostructure. *Clin Plast Surg* 24(2):347–367
19. Leboulanger N, Blanchard M, Denoyelle F, Glynn F, Charrier J-B, Roger G, Monteil J-P, Garabedian E-N (2011) Autologous fat transfer in velopharyngeal insufficiency: indications and results of a 25 procedures series. *Int J Ped Otorhinolaryngol* 75:1404–1407
20. Cantarella G, Mazzola RF, Mantivani M, Baracca G, Pignataro L (2011) Treatment of velopharyngeal insufficiency by pharyngeal and velar fat injections. *Otolaryngol Head Neck Surg* 145:401–403
21. Cao Y, Tingting M, Di W, Ningbei Y, Zhenmin Z (2013) Autologous fat injection combined with palatoplasty and pharyngoplasty for velopharyngeal insufficiency and Cleft palate: preliminary experience. *Otolaryngol Head Neck Surg* 149:284–291
22. Marchand F (1919) Ueber die Verandeungen des Fettgewebes nach der Transplantation. *Beitr Pathol Anat Allg Pathol* 66:32
23. Neuhof H (1923) The transplantation of tissues. D. Appleton & Co, New York
24. Peer LA (1956) The neglected free fat graft. *Plast Reconstr Surg* 18:233
25. Rieck B, Schlaak S (2003) Measurement in vivo of the survival rate in autologous adipocyte transplantation. *Plast Reconstr Surg* 111:2315
26. Har-Shai Y, Lindenbaum ES, Gamliel-Lazarovich A et al (1999) An integrated approach for increasing the survival of autologous fat grafts in the treatment of contour defects. *Plast Reconstr Surg* 104:945
27. Karacalar A, Orak I, Kaplan S et al (2004) No touch technique for autologous fat harvesting. *Aesthetic Plast Surg* 28:158
28. Nguyen A, Pasyk KA, Bouvier TN et al (1990) Comparative study of survival of autologous adipose tissue taken and transplanted by different techniques. *Plast Reconstr Surg* 85:378
29. Palma PC et al (2003) Effect of purified collagen on lipograft survival: experimental basis for periurethral lipoinjections. *J Endourol* 17:255
30. Chan CW, McCulley SJ, Macmillan RD (2008) Autologous fat transfer—a review of the literature with a focus on breast cancer surgery. *J of Plast Reconstr and Aesthet Surg.* 61:1438–1448
31. Von Heimburg D et al (2004) Comparison of viable cell yield from excised versus aspirated adipose tissue. *Cells Tissues Organs* 178:87–92
32. Rohrich RD et al (2004) In search of improved fat transfer viability: a quantitative analysis of the role of centrifugation and harvest site. *Plast Reconstr Surg* 113:391
33. Kaufman MR, Miller TA, Huang C, Roostaien J, Wasson KL, Ashley RK, Bradley JP (2007) Autologous fat transfer for facial recontouring: is there science behind the art? *Plast Reconstr Surg* 119(7):2287–2296
34. Filip C, Matzen M, Aagenaes I et al (2011) Speech and magnetic resonance imaging results following autologous fat transplantation to the velopharynx in patients with velopharyngeal insufficiency. *Cleft Palate Craniofac J* 48:708–716
35. Bardot J, Salazard B, Casanova D, Pech C, Magalon G (2007) Les séquelles vélopharyngées dans les fentes labio-alvéolopalatovélaire: pharyngoplastie par lipostructure du pharynx. *Rev Stomatol Chir Maxillofac* 108:352–358
36. Teixeira RP, Reid JA, Greensmith A (2011) Fatty hypertrophy cause obstructive sleep apnea after fat injection for velopharyngeal incompetence. *Cleft Palate Craniofac J* 48:473–477
37. Lazzeri D et al (2012) Blindness following cosmetic injections of the face. *Plast Reconstr Surg* 129(4):995–1012
38. Marom T, Roth Y, Goldfarb A, Cinamon U (2012) Head and neck manifestations of 22q11.2 deletion syndromes. *Eur Arch Otorhinolaryngol* 269:381–387
39. Jianhui Z, Chenggang Y, Binglun L et al (2014) Autologous fat graft and bone marrow-derived mesenchymal stem cells assisted fat graft for treatment of Parry-Romberg syndrome. *Ann Plast Surg* 73(suppl 1):S99–S103